



Clinical  
Case Studies



# Puros<sup>®</sup> Allograft Customized Block







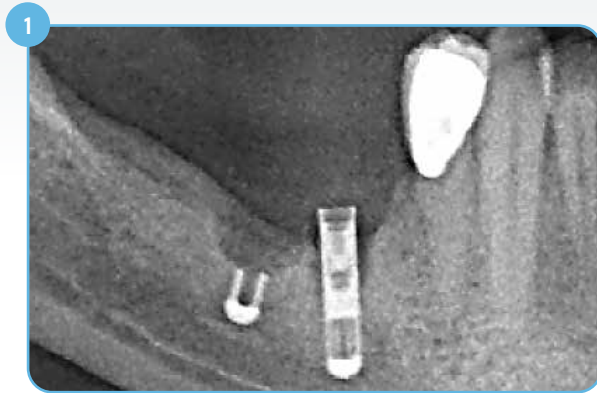## Table of Contents

### Clinical Case Studies using Puros Allograft Customized Block

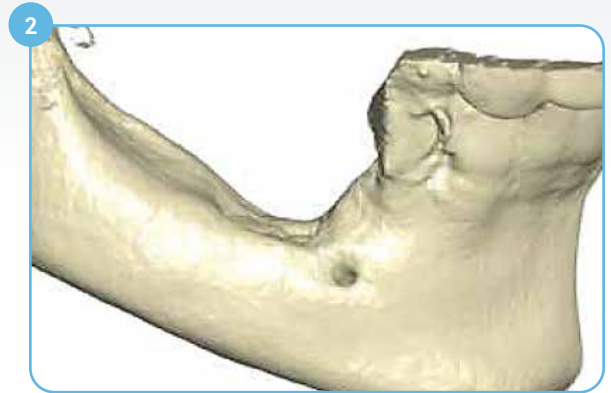<b>Case 1:</b> Failed implant removed and grafted with Puros Custom Block. Six-month re-entry and implant placement	4
<b>Case 2:</b> Two implants placed five months after grafting with Puros Custom Block in maxillary incisors. Two-year follow-up: Stable crestal bone level around implant shoulders	6
<b>Case 3:</b> Combined horizontal and vertical defect in posterior mandible: 4.5 year follow up	10
<b>Case 4:</b> Sinus floor augmentation: 2, 3, and 4 year follow-up	13
Ordering Information	18

## Case 1\*

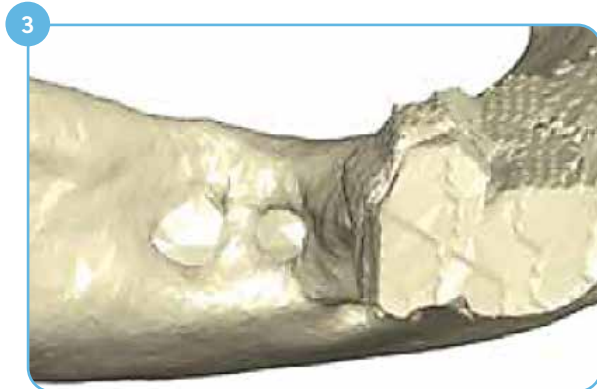Failed implant removed and grafted with Puros Custom Block. Six-month re-entry and implant placement



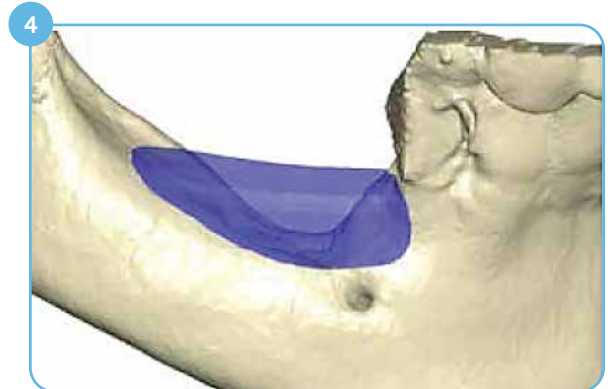
1 Initial situation: More than 50% of implant length exposed due to bone loss; failed implants need to be removed.



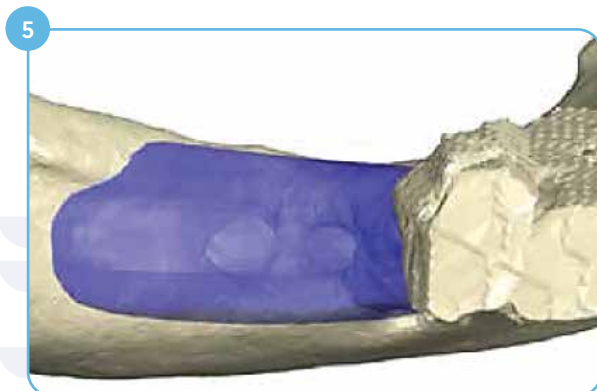2 Three-dimensional reconstruction of the defect, lateral view.



3 Three-dimensional reconstruction of the defect, occlusal view.



4 Designed bone block, lateral view.



5 Designed bone block, occlusal view.

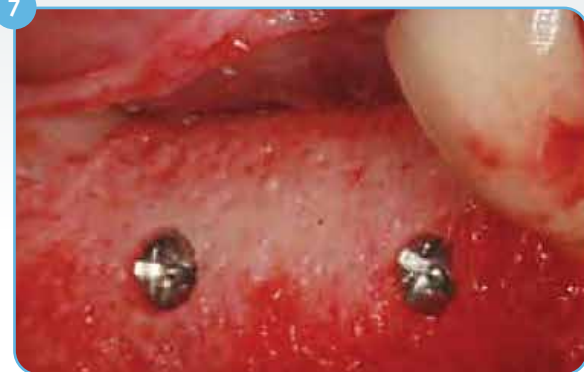

6 Milled Puros Allograft Customized Block.

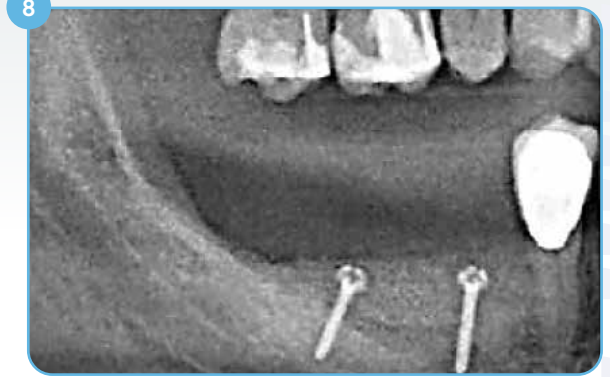
Case photos courtesy of Dr. K. K. Würzler.

\*Clinical case pictures presented are based on the history of Puros Customized Block in regions outside North America.

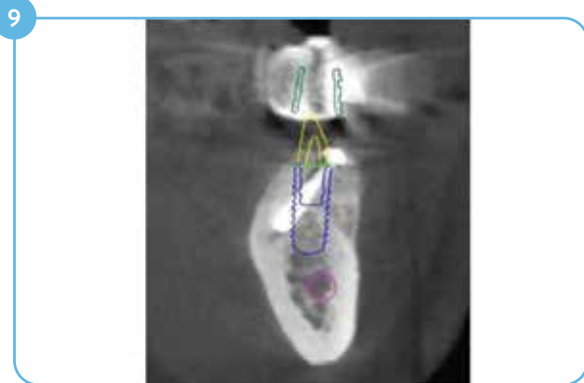## Clinical Case #1 (continued)



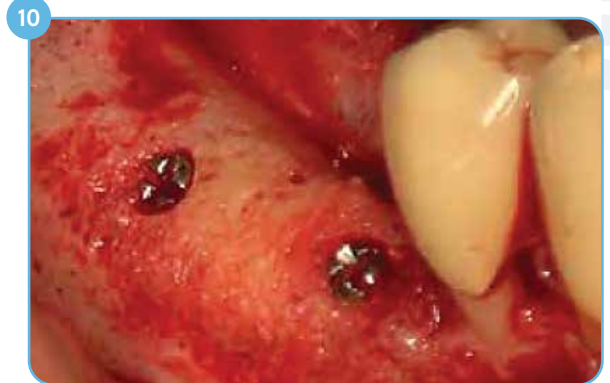Fixed bone block placed; Screw heads in tight contact with bone.



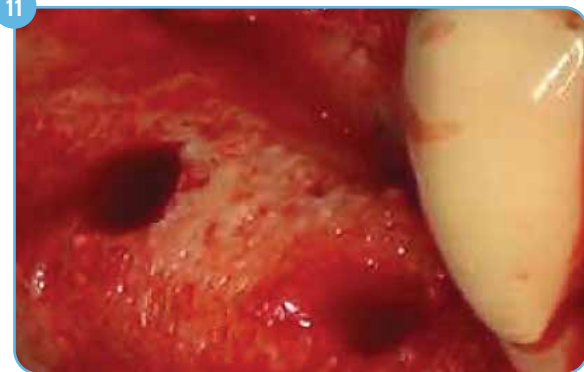Post-operative radiograph



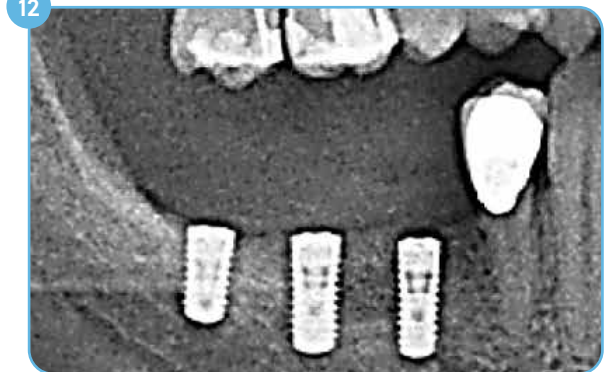
3D diagnostics and implant planning, 6 months post-op.



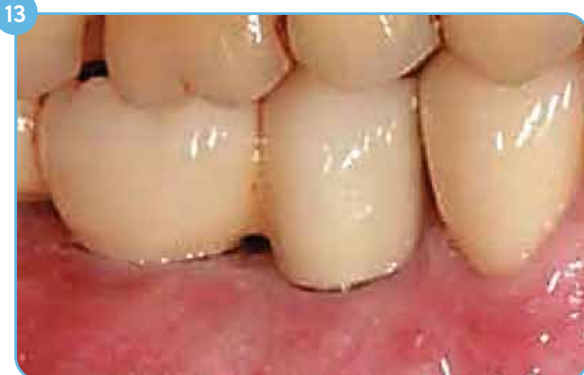Re-entry 6 months post-op, screws are in tight contact with bone.



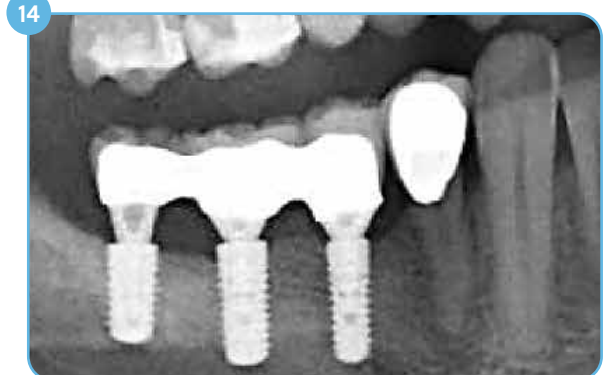Vital bone bed.



Radiograph after implant placement.



Final aesthetic restoration 10 months post-augmentation.

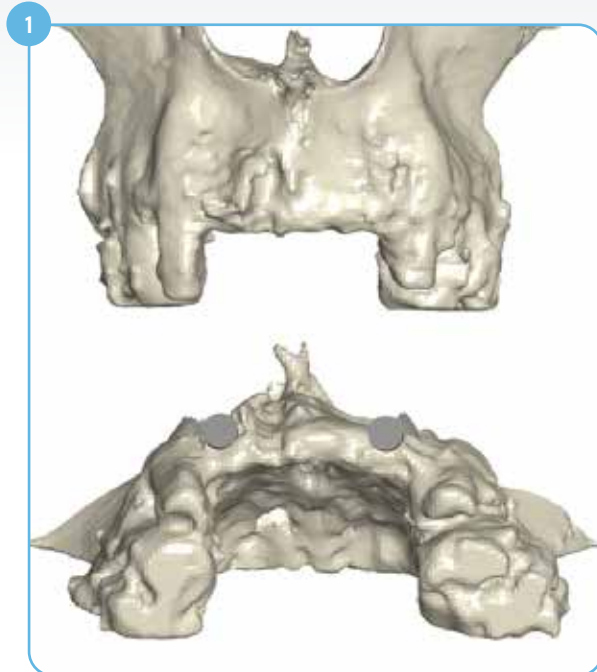

One-year follow-up.

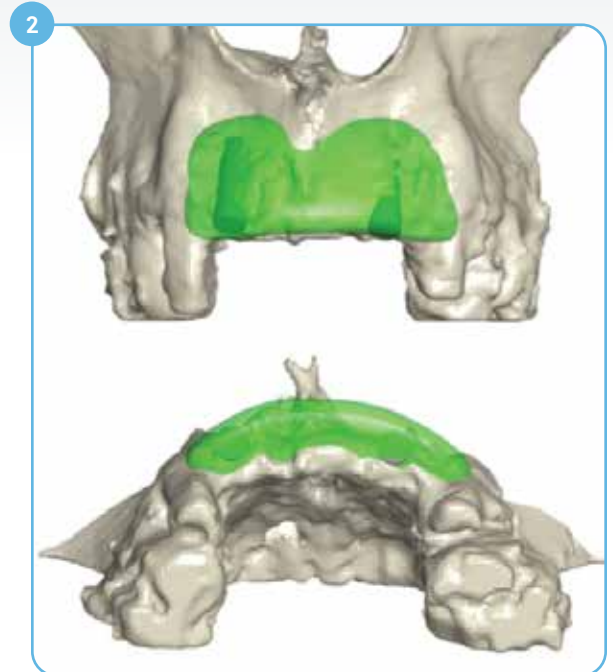
## Clinical Case #2\*

Two implants placed five months post-op (Maxillary Incisors)

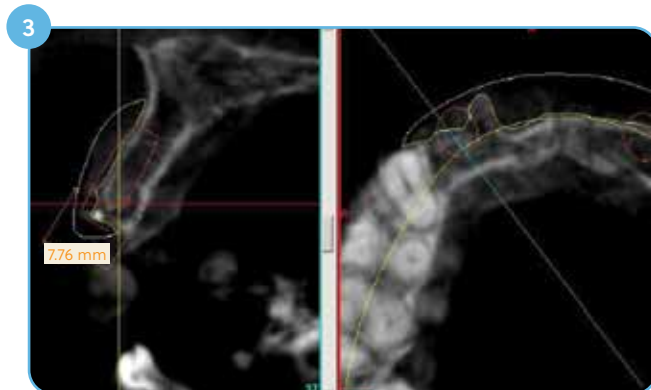
Two-year post-op: Stable crestal bone level around implant shoulders



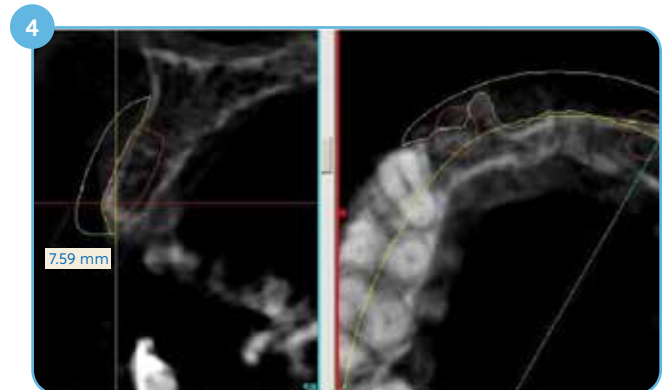
Failed site after autologous grafting; Horizontal augmentation needed; Two 4 mm Ø cylindrical implant placed for reference.



Green object represents the designed custom block.



Cross section at tooth position #7 (maxillary lateral incisor); Yellow contour represents the designed custom block.



Cross section at tooth position #10 (maxillary lateral incisor).

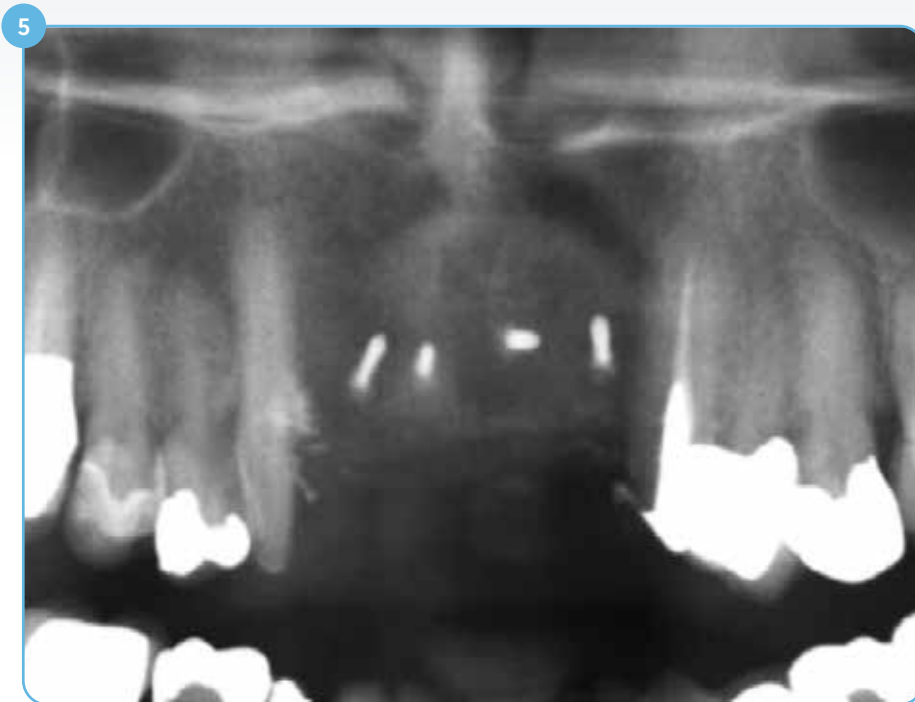Case photos courtesy of Dr. Christian Buhtz.

\*Clinical case pictures presented are based on the history of Puros Customized Block in regions outside North America.



## Clinical Case #2 (continued)

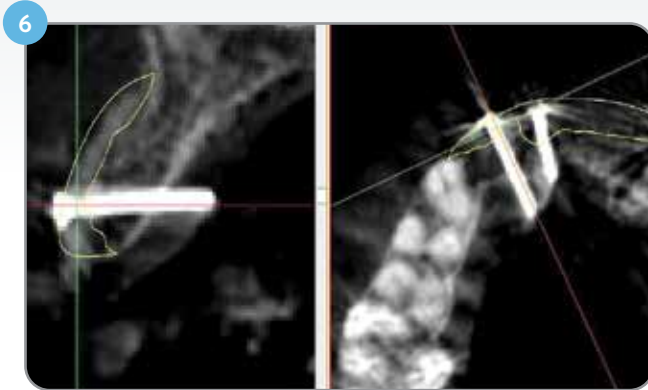
Post-grafting



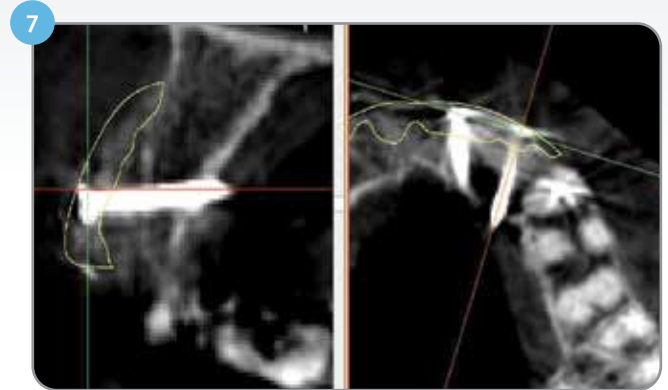
Post-grafting radiograph; block fixed with four screws.

## Clinical Case #2 (continued)

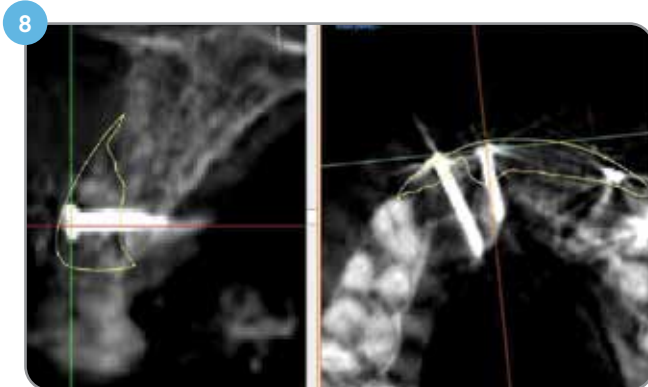
Five months post-op



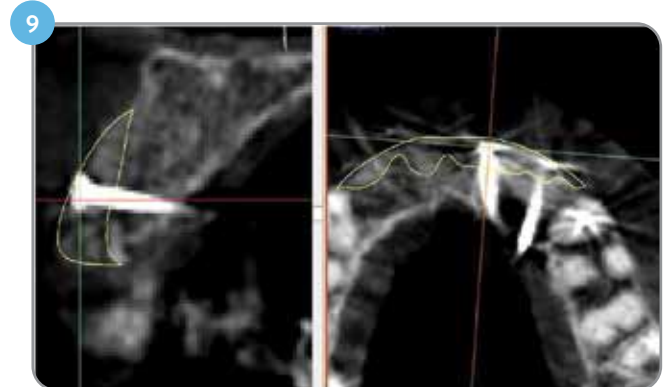
Five months post-grafting CBCT-scan superimposed with designed block (yellow contour). Tooth position #7 (maxillary lateral incisor).



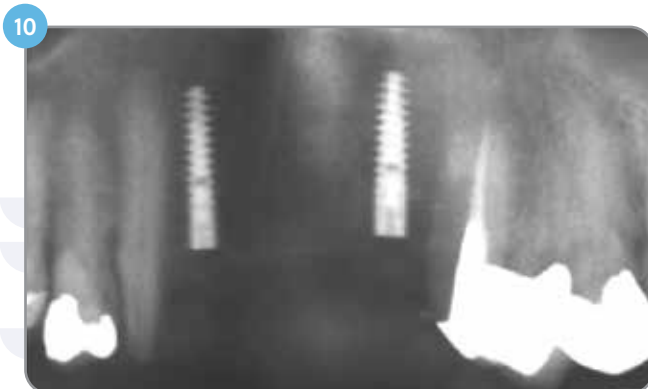
Five months post-grafting CBCT-scan superimposed with designed block (yellow contour) shows stable bone volume after five months. Tooth position #10 (maxillary lateral incisor).



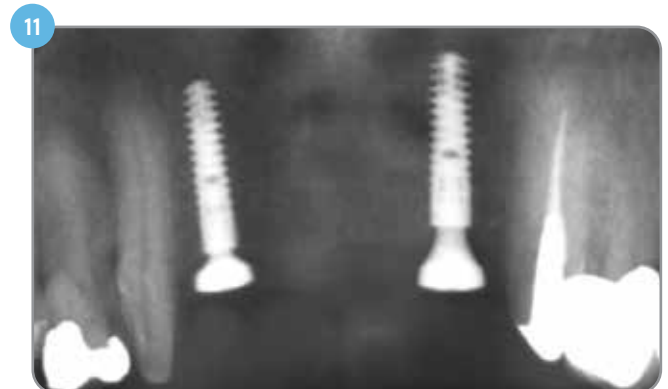Five months post-grafting CBCT-scan superimposed with designed block (yellow contour). Tooth position #8 (maxillary central incisor).



Five months post-grafting CBCT-scan superimposed with designed block (yellow contour). Tooth position #9 (maxillary central incisor).



Five months after grafting: Two implants have been placed in tooth position #7 (maxillary lateral incisor) and tooth position #10 (maxillary lateral incisor).



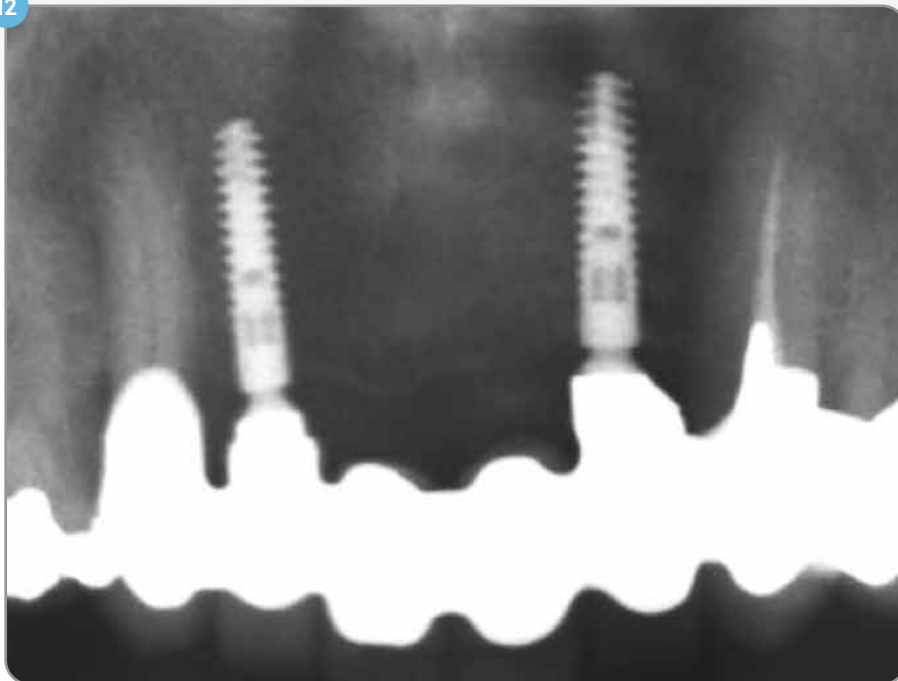
Radiograph after uncovering of the implants three months after implant placement; bone level maintained up to crest of implant.



## Clinical Case #2 (continued)

Two years post-loading: stable crestal bone levels around implants

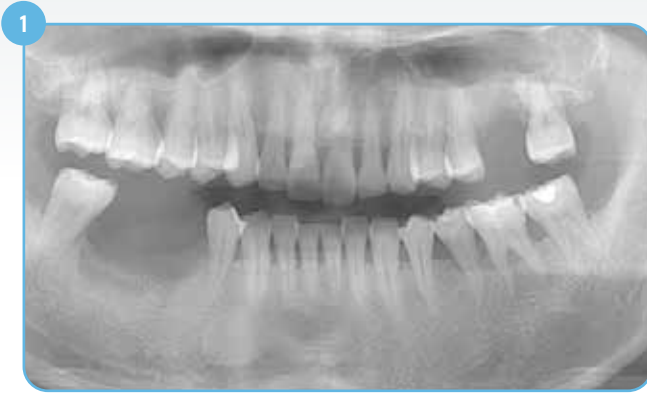12



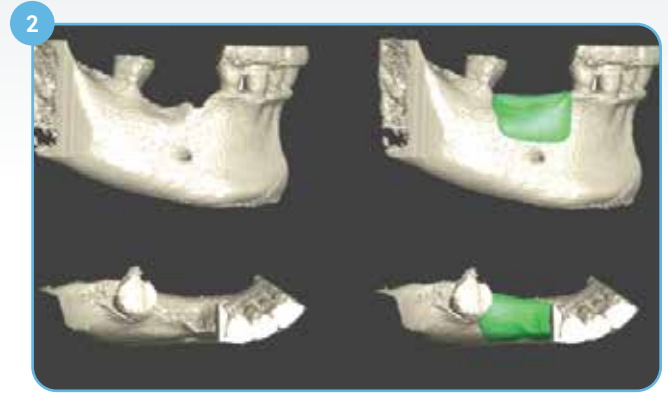
Radiograph two years after implant loading. Stable bony levels at implant shoulders (both mesial and distal).

## Clinical Case #3\*

Combined horizontal and vertical defect in posterior mandible: 4.5 year follow up



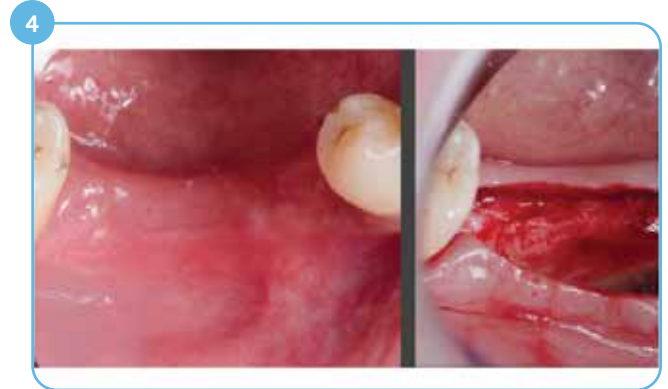1 Combined horizontal and vertical defect.



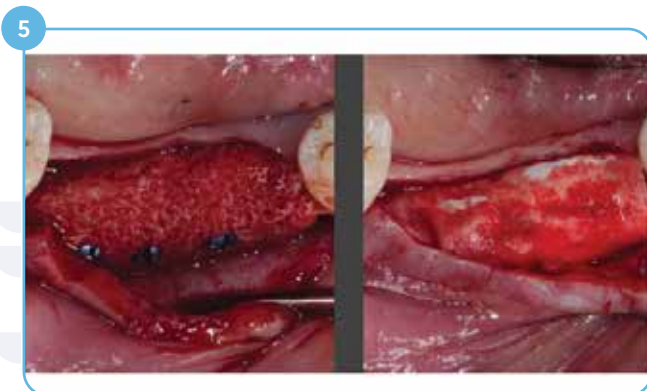
2 Green object represents the designed block.



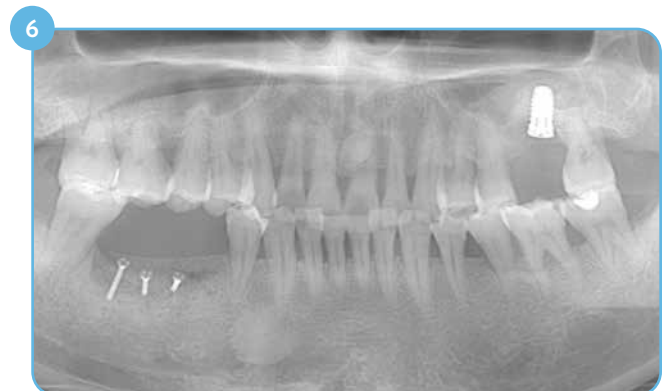3 Milled block for the defect.



4 Mid-crestal incision.



5 Custom block fixed with three screws.

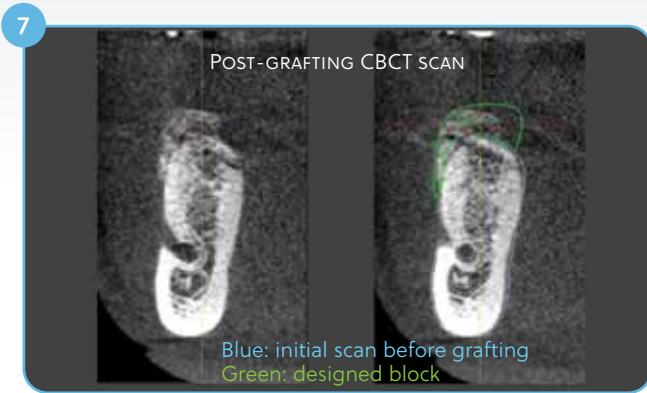


Case photos courtesy of Dr. Marc Hinze.

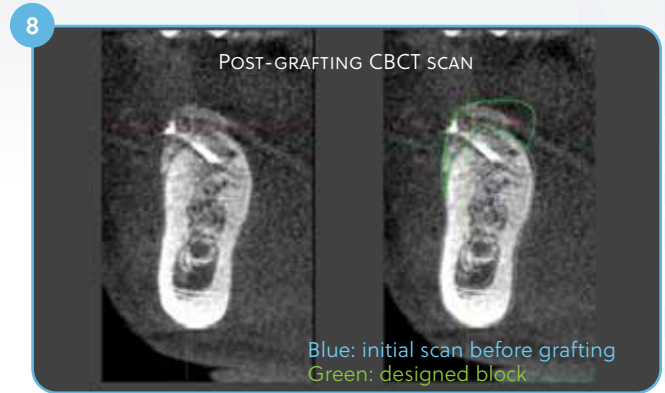
\*Clinical case pictures presented are based on the history of Puros Customized Block in regions outside North America.

## Clinical Case #3 (continued)

Post-grafting scans

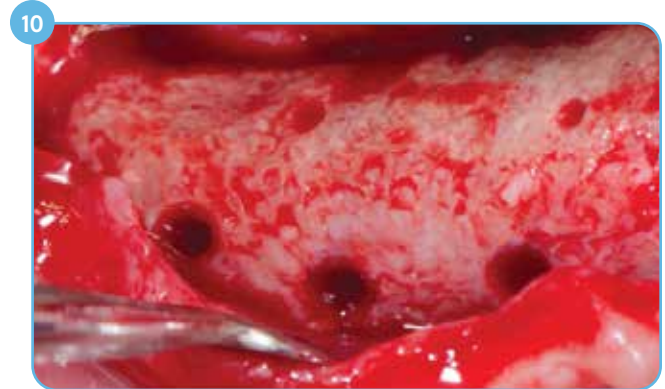
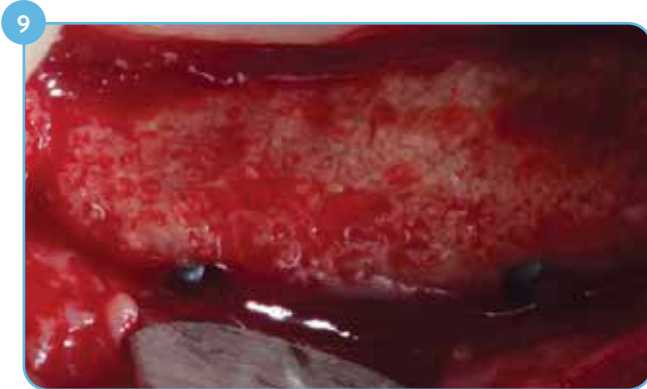

Post-grafting CBCT scan good fit, deviation lingually. Tooth position #29 (mandibular second pre-molar).

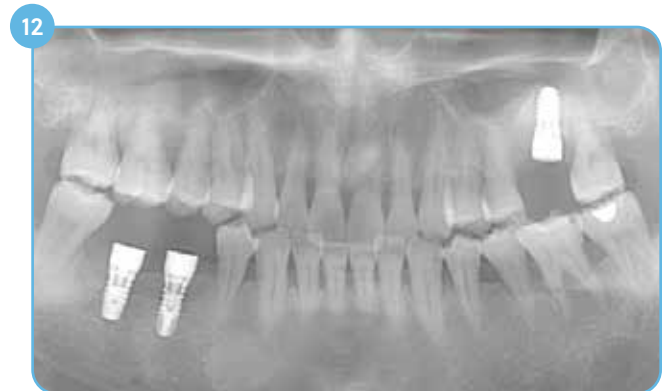
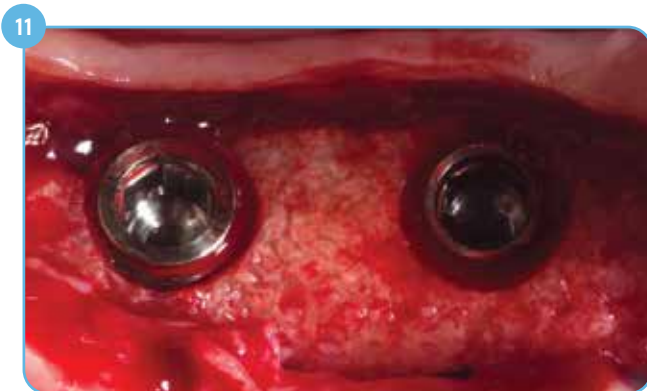
Post-grafting CBCT scan good fit, deviation lingually. Tooth position #30 (mandibular first molar).

Five months re-entry; no resorption at screw heads



Uneventful healing; no resorption - head of the screw is in complete contact with bone.



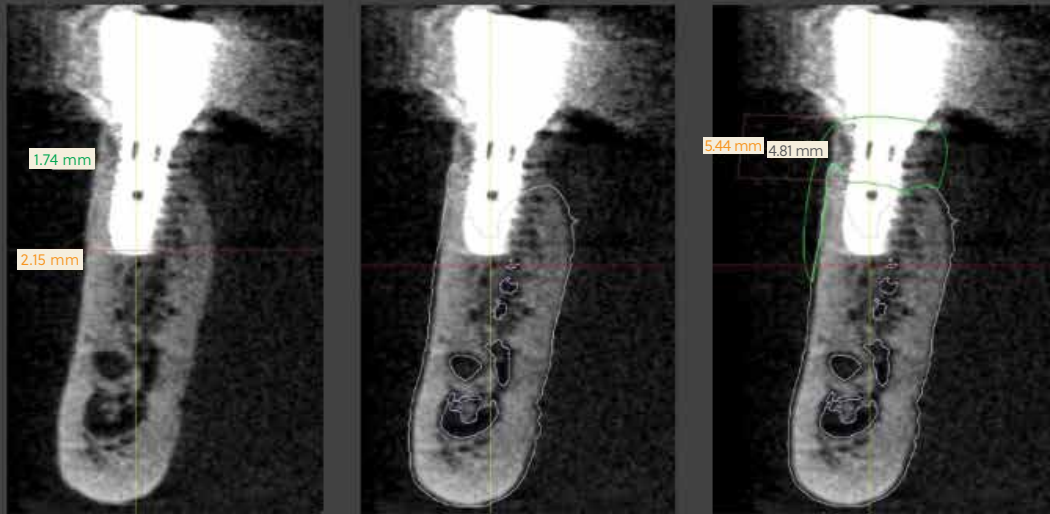
Cancellous structure of the custom block covered with a thin layer of cortical bone.

Case photos courtesy of Dr. Marc Hinze.

## Clinical Case #3 (continued)

Four-and-a-half-year post-op CBCT scans shows significant gain of vertical bone

13



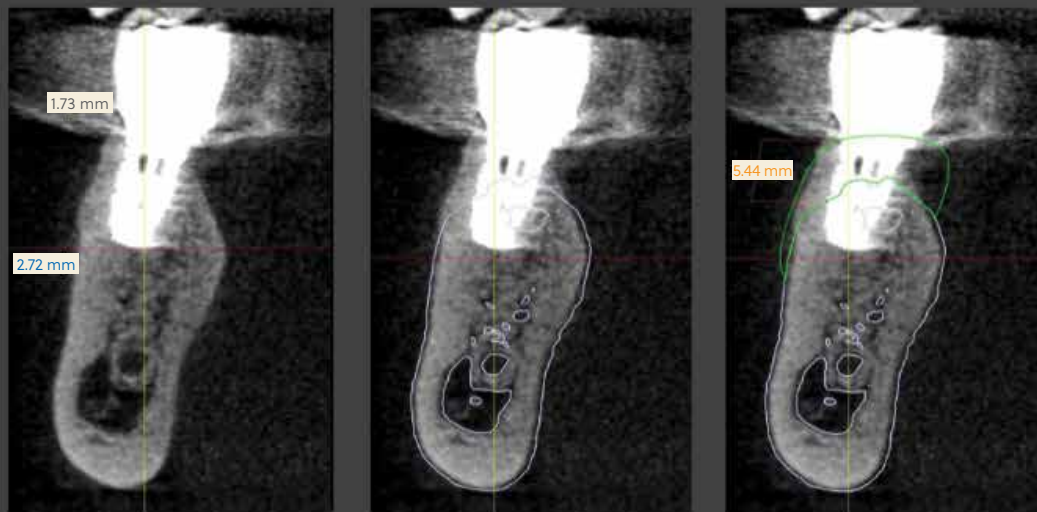
4.5y follow-up CBCT scan

4.5y follow up CBCT scan  
Blue: initial scan before grafting

4.5y follow up CBCT scan  
Blue: initial scan before grafting  
Green: designed block

Four-and-a-half-year follow-up CBCT scan shows vertical gain of 4.8 mm (vs. 5.4 mm planned), thick buccal plate 1.74 – 2.19 mm). Tooth position #29 (mandibular second pre-molar).

14



4.5y follow up CBCT scan

4.5y follow up CBCT scan  
Blue: initial scan before grafting

4.5y follow up CBCT scan  
Blue: initial scan before grafting  
Green: designed block

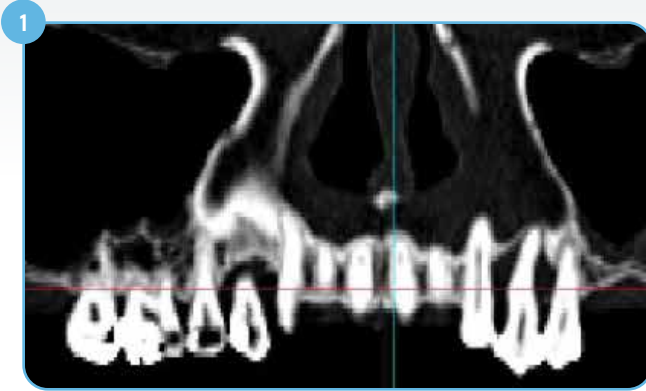
Four-and-a-half-year follow-up CBCT scan shows vertical gain of 5.32 mm (planned), thick buccal plate (1.73 – 2.72 mm). Tooth position #30 (mandibular first molar).

Case photos courtesy of Dr. Marc Hinze.

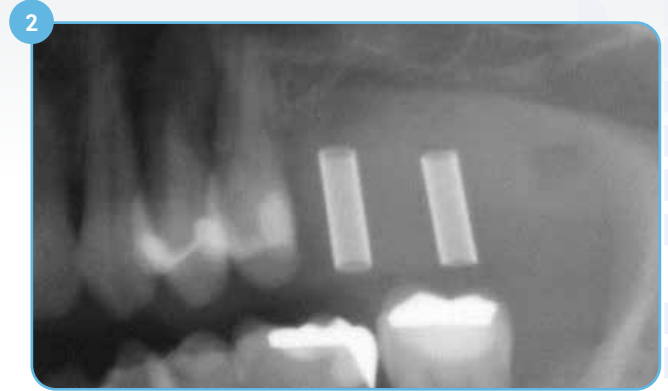


## Clinical Case #4\*

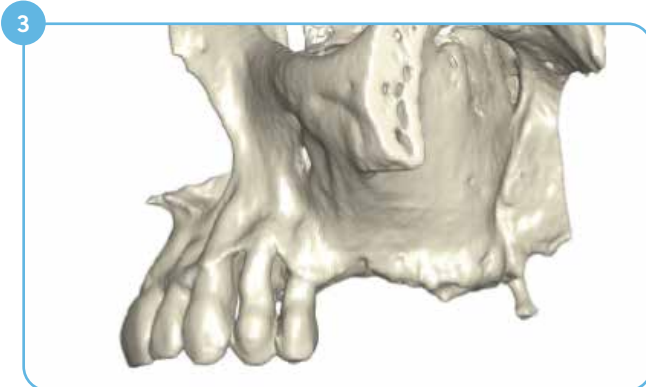
Vertical bone grating of the sinus floor



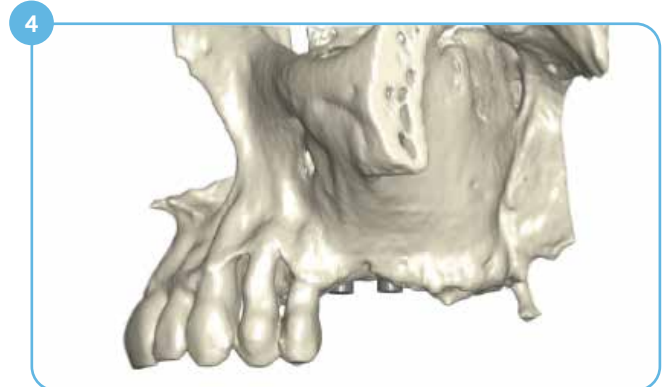
1 Initial situation, CT scan shows vertical defect at tooth position #14 and #15.



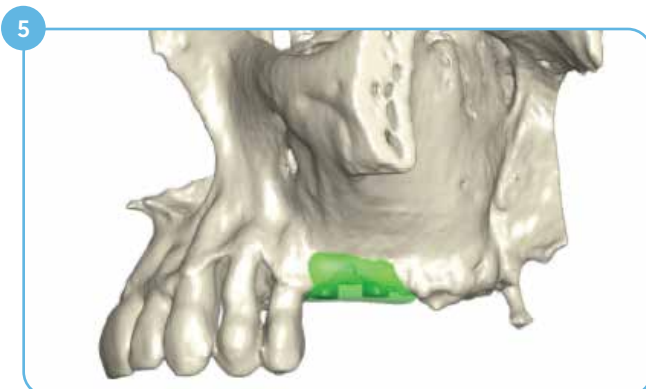
2 Initial situation, X-ray shows vertical defect at tooth position #14 and #15.



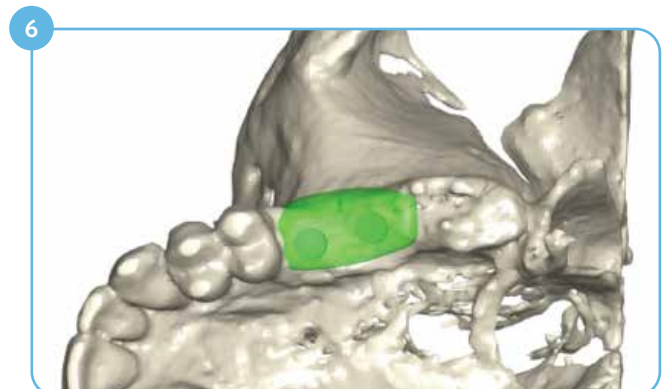
3 3D model of the left maxilla after segmentation of the CT scan.



4 Lateral view: Two implants (4.3x11 mm) have been placed in the 3D model for reference; implant shoulders requiring bone augmentation.



5 A bone block has been designed to reconstruct deficient sinus floor at tooth position #14 and #15.



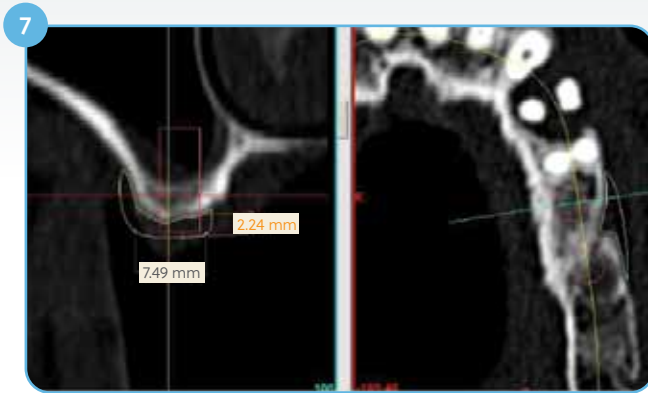6 Occlusal view: A bone block has been designed to reconstruct deficient sinus floor at tooth position #14 and #15.

Case photos courtesy of Dr. Simone Esser.

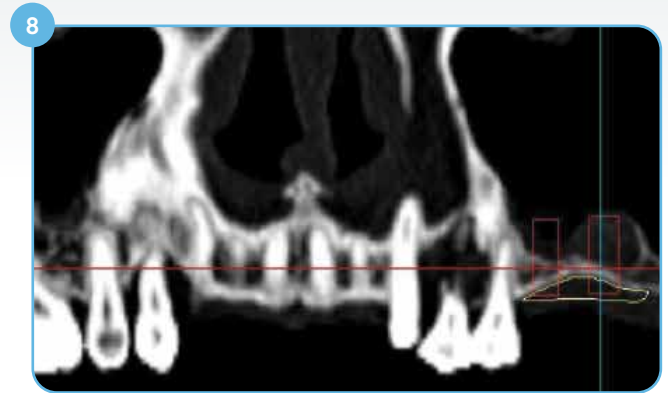\*Clinical case pictures presented are based on the history of Puros Customized Block in regions outside North America.

## Clinical Case #4 (continued)

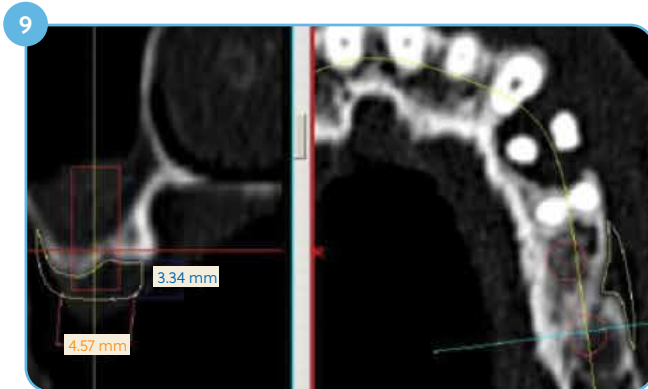Sinus floor augmentation



Cross section at tooth position #14 (maxillary first molar); yellow contour of the designed block fits nicely over the original scan.



Baseline CT scan superimposed with implants (red) and designed bone block (yellow).



Cross section at tooth position #15 (maxillary second molar).

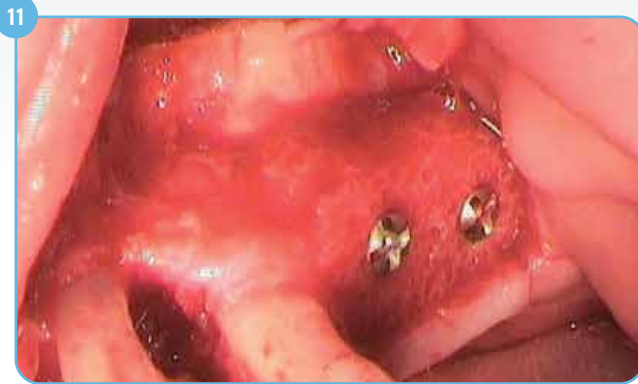

Milled Puros Allograft Customized Block.

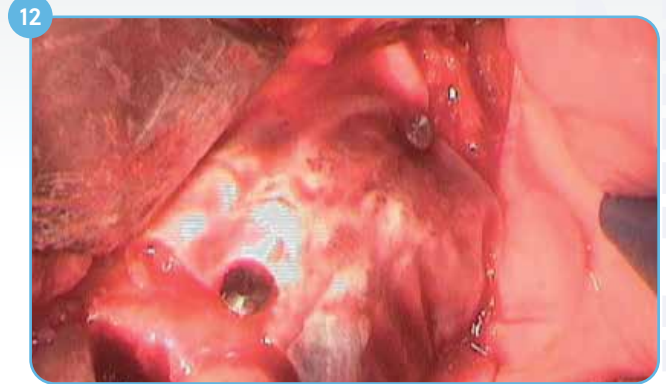

## Clinical Case #4 (continued)

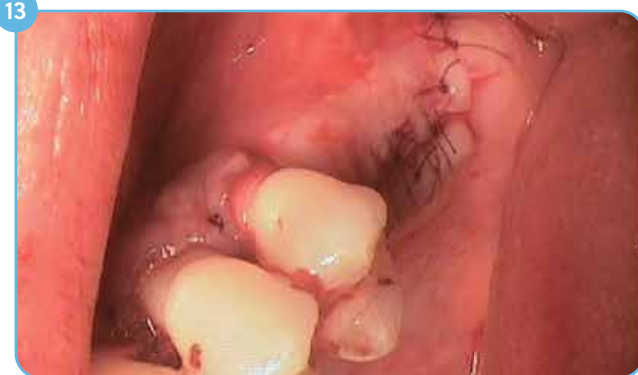### Sinus floor augmentation



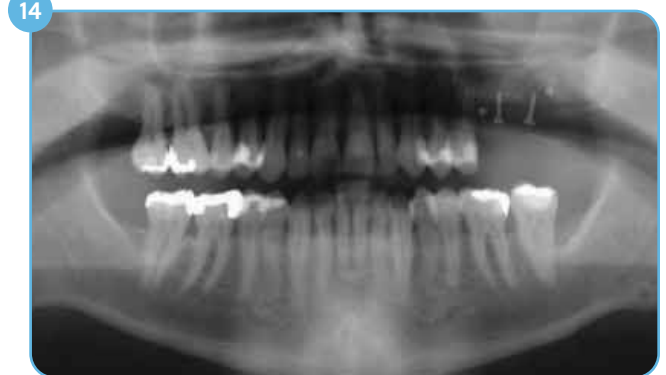11 Puros Allograft Customized Block fixed with two fixation screws.



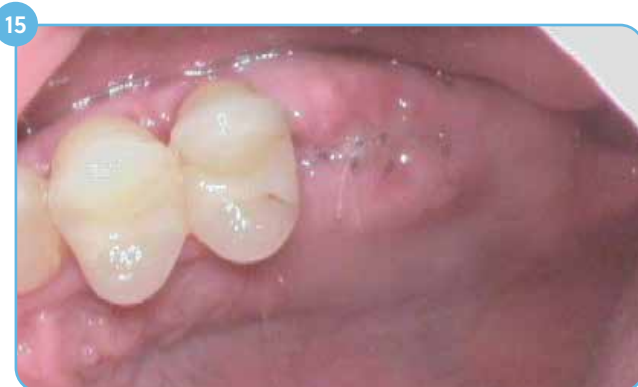12 Grafted site covered with a CopiOs® Pericardium Membrane.



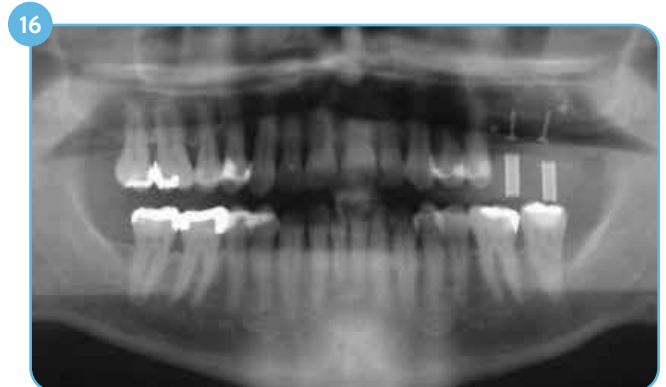13 Tension-free wound closure.



14 Post-grafting radiograph.



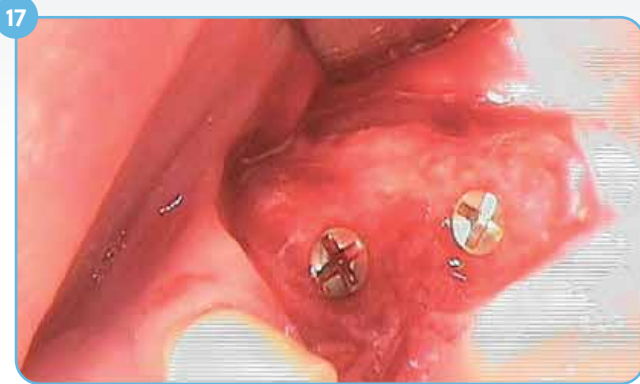15 Soft-tissue healing eight days post-grafting.



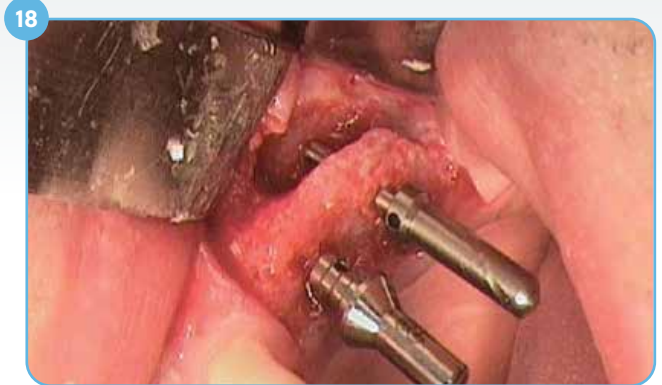16 Radiograph six months post-grafting.

## Clinical Case #4 (continued)

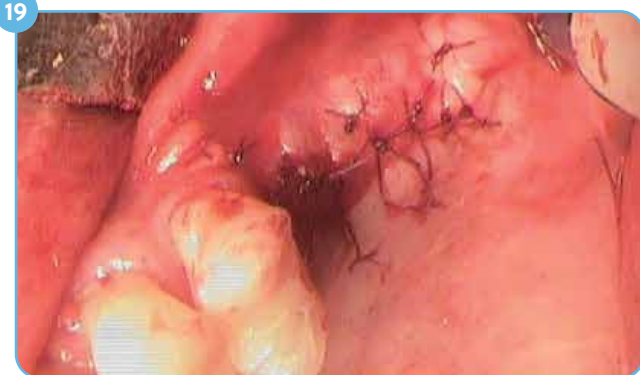Implant placement six months after grafting



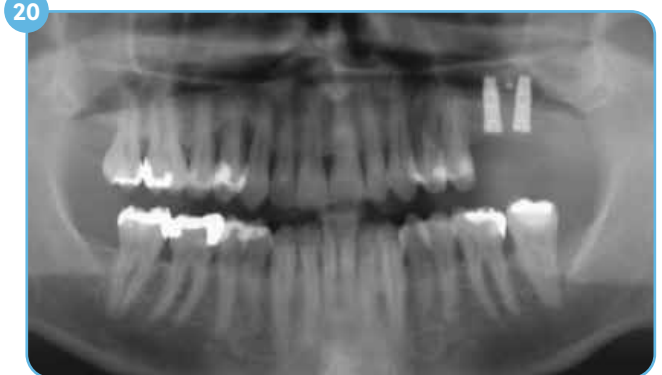17 Clinical situation six months post-grafting during re-entry, well integrated bone block with minimal signs of resorption.



18 Two T3® Implants 4x11.5 mm have been placed with simultaneous sinus grafting using autogenous bone; sufficient sinus floor thickness achieved for implant placement.



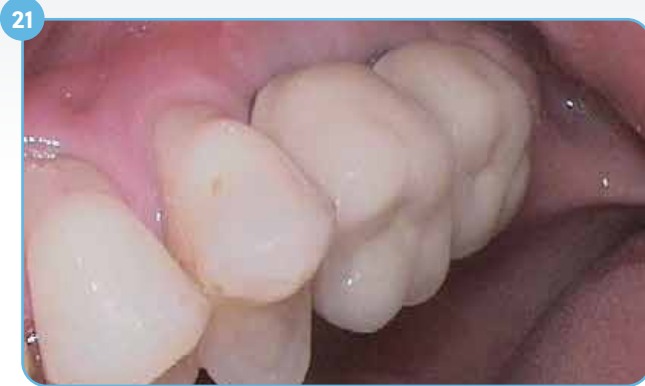19 Tension-free wound closure after implant placement and sinus lift.



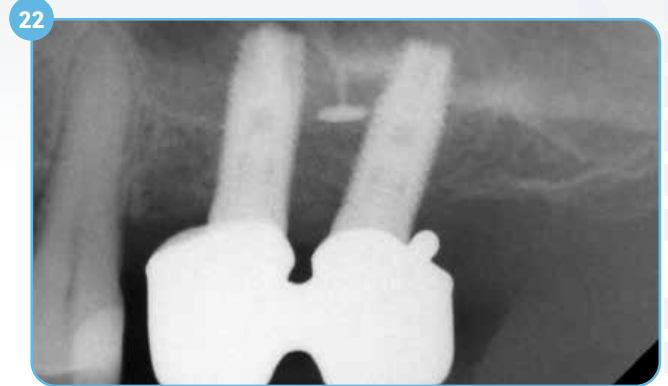20 Radiograph post-implantation.

## Clinical Case #4 (continued)

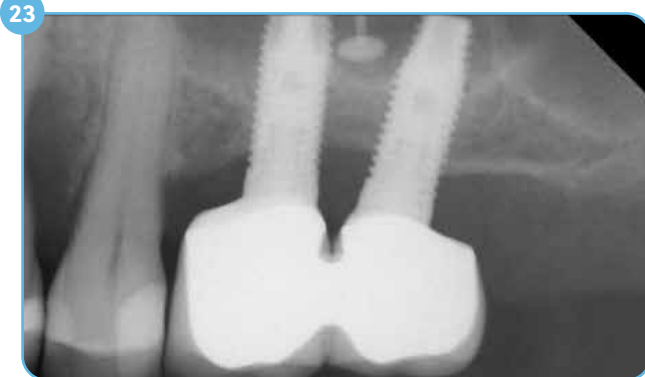Two, three, and four-year follow-ups



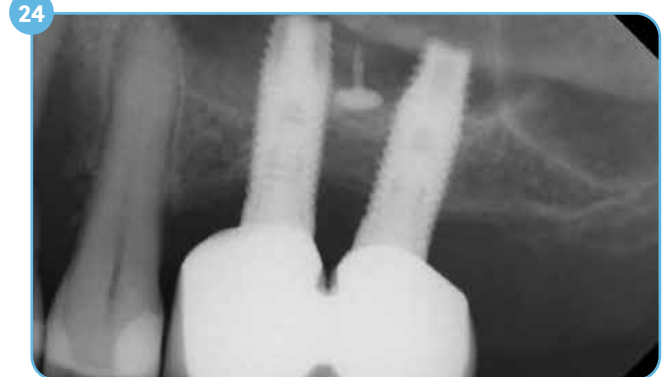
Screw-retained final restoration in place six months after implant placement.



Two-year follow-up radiograph; implant in stable condition.



Three-year follow-up radiograph.



Four-year follow-up radiograph; implant in stable condition.

## Ordering Information

SKU	Description	Dimensions
68217	PUROS ALLOGRAFT CUSTOMIZED BLOCK, STANDARD SIZE	Min. Dimension: 5 mm x 1 mm x 1 mm Max. Dimension: 27 mm x 15 mm x 15 mm
68218	PUROS ALLOGRAFT CUSTOMIZED BLOCK, LARGE SIZE	Min. Dimension: 27.1 mm x 15.1 mm 15.1 mm Max. Dimension: 60 mm x 30 mm x 30 mm





For more information, visit [ZimVie.com](https://www.zimvie.com)

ZimVie  
4555 Riverside Drive  
Palm Beach Gardens, FL 33410



Unless otherwise indicated, as referenced herein, all trademarks and intellectual property rights are the property of ZimVie Inc. or an affiliate; and all products are manufactured by one or more of the dental subsidiaries of ZimVie Inc. (Biomet 3i, LLC, Zimmer Dental, Inc., etc.) and marketed and distributed by ZimVie Dental and its authorized marketing partners. CopiOs Pericardium Membrane is processed by Tutogen Medical GmbH. Puros Allograft Customized Block is processed by Tutogen Medical GmbH. Tutoplast is a U.S. trademark owned by Tutogen Medical GmbH. For additional product information, please refer to the individual product labeling or instructions for use. HTIRW is manufactured by Elos Medtech Pinol A/S and distributed by ZimVie Dental. Product clearance and availability may be limited to certain countries/regions. This material is intended for clinicians only and does not comprise medical advice or recommendations. Distribution to any other recipient is prohibited. This material may not be copied or reprinted without the express written consent of ZimVie. ZV1914 REV A 11/23 ©2023 ZimVie. All rights reserved.

